Serial Ultrasound Imaging Leading up to an Achilles Tendon Rupture After Identification of a Thickened Paratenon

A Case Report

Kory Ford, MD,[1] Nick Monson, MD,[2] Sica Glauser, MA, LAT, ATC,[3] and Daniel M. Cushman, MD[1,2]

Abstract: A 22-yr-old lacrosse student-athlete had participated in a research study examining the Achilles tendons of asymptomatic athletes, with normal appearance of his Achilles tendons bilaterally 7 mos before injury. Around 4 wks before injury, the patient started to report achy pain in the affected Achilles tendon, exacerbated by ankle dorsiflexion and plantarflexion, in the context of using new cleats during conditioning. He underwent repeat ultrasound assessment, identifying a normal appearing Achilles tendon, though with new hypoechogenic paratenon thickening approximately 1–4 cm proximal to the calcaneus. He ultimately suffered a noncontact complete Achilles tendon rupture. This case is the second known example of an Achilles tendon rupture with previous asymptomatic advanced imaging and additionally calls into question the role of the Achilles paratenon in Achilles tendon pathology and rupture.

Key Words: Paratenon, Paratenonitis, Tendinitis, Tendinopathy, Case Report

(*Am J Phys Med Rehabil* 2025;104:1067–1069)

The Achilles tendon functions to assist in plantarflexion and hindfoot inversion and has been described as the strongest and largest tendon in the human body. It is also the most commonly injured tendon.[1] It may develop a variety of pathology with a range of severity, the most severe being an Achilles tendon rupture (ATR). This typically manifests as a sudden snap or pop during a single high-load dorsiflexion maneuver and is often accompanied by a rapid acceleration-deceleration mechanism.[2] Patients will present with swelling in the posterior ankle region, difficulty with plantarflexion, and often have difficulty bearing weight through the affected limb.[3] The rise of ATR incidence over the last several years to decades is notable, with 60%–75% of Achilles tendon ruptures associated with participation in sports, and more commonly occurring in men.[3]

From the [1]Department of Physical Medicine & Rehabilitation, University of Utah, Salt Lake City, Utah; [2]Department of Orthopaedics, University of Utah, Salt Lake City, Utah; and [3]Department of Athletics, University of Utah, Salt Lake City, Utah.

All correspondence should be addressed to: Dan Cushman, MD, Department of Physical Medicine & Rehabilitation, Department of Orthopaedics, University of Utah, 590 Wakara Way, Salt Lake City, UT 84108.

Kory Ford is in training.

Author Disclosures: Dr. Monson reports receiving funding from Trice Medical, outside the submitted work. The authors report no competing interests, funding or grants or equipment provided for the project from any source, financial benefits, or previous presentation of the research, manuscript, or abstract in any form.

Financial disclosure statements have been obtained, and no conflicts of interest have been reported by the authors or by any individuals in control of the content of this article.

Copyright © 2025 Wolters Kluwer Health, Inc. All rights reserved.

ISSN: 0894-9115

DOI: 10.1097/PHM.0000000000002826

It remains unclear whether ATR is associated with tendinopathy and predisposing changes to the Achilles tendon and surrounding paratenon. It has been theorized that degenerative changes affect the integrity of the tissue and predispose an athlete to ATR. Inflammatory cells may proliferate and infiltrate the Achilles and paratenon, compromising tissue quality. Additional features, such as calcifications and watershed vascular supply, may also play a role. [4]

The role of the Achilles paratenon has been less well-studied. It is defined as the tissue surrounding the Achilles tendon, or the outermost layer of the tendon,[5] and has previously been identified as a likely source of tendon progenitor cells in addition to being a critical source of blood supply to the Achilles tendon during normal function and development.[6] It has also historically been implicated in peri-Achilles posterior ankle pain (paratenonitis), thought to be due to an acute stress response involving inflammatory cells and capillary proliferation within the paratenon.[7] After ATR specifically, rat models have found that an intact paratenon leads to improved healing of the Achilles tendon,[5] indicating the importance of the role of the paratenon on both Achilles tendon pathology and healing. This study conforms to all CARE guidelines and reports the required information accordingly (see Supplementary Checklist).

CASE PRESENTATION

Seven months before a right Achilles tendon rupture, a 22-yr-old collegiate lacrosse midfielder with 15 yrs of lacrosse experience and no previous Achilles tendon issues had participated in a research study examining the Achilles tendons of numerous asymptomatic athletes. This study included an ultrasound evaluation of the tendons (Sonosite PX, 15-MHz linear probe) by an experienced sonographer, in which a video was recorded of each tendon in transverse and sagittal planes (Figs. 1A, B). Two experienced, blinded reviewers reviewed these videos shortly thereafter and identified no abnormalities in the tendon, namely, hypoechogenicity, thickening, or neovascularity on power Doppler imaging.

Around 4 wks before his ATR, the patient started to report achy pain in the affected Achilles tendon, exacerbated by movements requiring both dorsiflexion and plantarflexion. This was in the context of using new cleats during conditioning. The athlete described persistent pain and rubbing along the posterior aspect of his Achilles with subjective "creakiness." He was evaluated by a sports medicine-trained physician about 2 wks before his ATR, and his physical exam was notable for tenderness in the Achilles tendon 2–3 cm proximal to the calcaneal insertion, with full range of motion and strength, with a negative Thompson's test. He underwent repeat ultrasound assessment with more thorough screening of the soft

Copyright © 2025 Wolters Kluwer Health, Inc. All rights reserved.

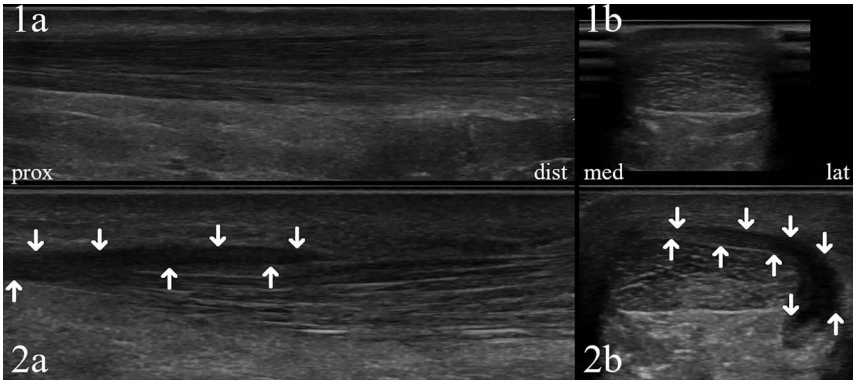

FIGURE 1. Ultrasound images of the Achilles tendon at time point 1 (preseason) and 2 (2 wks before rupture). The "A" images show long-axis view, while "B" images show short-axis view of the Achilles tendon. The arrows outline the thickened paratenon. Abbreviations: "prox" proximal, "dist" distal, "med" medial, "lat" lateral.

tissue elements of the posterior, medial, and lateral lower leg, ankle, and foot. This identified a normal appearing Achilles tendon, but with hypoechogenic paratenon thickening on the medial superficial surface of the tendon extending into the crural fascia, approximately 1–4 cm proximal to the calcaneus (Figs. 1, 2A, B). No other abnormalities were identified. Of specific interest, the plantaris tendon was found to be intact and without pathology. He was prescribed meloxicam as needed for pain and instructed to trial gel heel cups and continue regular conditioning. Additionally, he participated in a directed eccentric rehabilitation program that also included proprioceptive control training and motor control training, with additional focus on core, hip girdle, and quad/hamstring strengthening.

On the day of the ATR, he reported generalized fatigue, especially in the calves and quadriceps musculature bilaterally. He described Achilles tendon pain similar to the previous 3–4 wks and took meloxicam as prescribed by the team physician. He had not taken any medications associated with tendon rupture (glucocorticoids, anabolic steroids, fluoroquinolones, renin-angiotensin II receptor antagonists, etc.). He sustained an in-game right Achilles tendon rupture during the push-off phase of his gait.

Immediately after the injury, his exam was remarkable for a positive Thompson's test with palpable gapping, tenderness to palpation about the midsubstance of the tendon, and 1/5 plantar flexion strength. An magnetic resonance imaging of

FIGURE 2. Magnetic resonance imaging completed 2 days after injury, indicating complete Achilles tendon rupture. Image "A": sagittal proton density sequence. Image "B": coronal T2 fat-saturated sequence. Image "C": sagittal short tau inversion recovery sequence. Image "d": axial proton density fat-saturated sequence.

© 2025 Wolters Kluwer Health, Inc. All rights reserved.

Copyright © 2025 Wolters Kluwer Health, Inc. All rights reserved.

the right ankle was performed 2 days after injury (Fig. 2), consistent with a complete Achilles tendon rupture, as well as severe tendinosis of the remnant distal Achilles tendon with normal calcaneal attachment. The paratenon did not rupture, and this was confirmed intraoperatively. A successful open repair was performed 5 days after the injury, with gradual return to play per standard postoperative protocol.

DISCUSSION

This case is the second known example of an Achilles tendon rupture with previous asymptomatic advanced imaging. The other known case described a female collegiate-level gymnast, who had a normal-appearing Achilles tendon on asymptomatic ultrasound evaluation done 8 mos before her ATR.[8] That case challenged the previously held dogma that Achilles tendon rupture happens as the last stage on a spectrum of progressive degeneration and tendinosis.[4] Previous studies have reported mixed histopathological changes after spontaneous ATR and are notable for a generally bimodal distribution of patient populations: older individuals with a sedentary lifestyle and younger athletes, namely, males aged 20–35.[3] According to the aforementioned case study,[8] it was plausible that in the younger athlete population, an ATR may occur without preceding tendinopathy and that the typical high-energy, rapid eccentric or explosive concentric loading force may be the primary and most important mechanism of injury, regardless of underlying pathology.[9] Thus, it was postulated that different mechanisms may be at play for these two populations.

Previous work rarely discusses the appearance or role of the Achilles paratenon in ATR. In this case, our patient not only had normal asymptomatic imaging 7 mos before his ATR but had symptomatic imaging 2 wks prior, which was notable for thickening of the Achilles paratenon, though with a normal appearing tendon proper. This could suggest a possible mechanism of ATR in young athletes. The paratenon, as discussed previously, is known to have tendon progenitor cells and play a role involving inflammatory cells and capillary proliferation during an acute stress response.[7] It has previously been noted that around 40% of gymnasts with ATR reported antecedent pain in the area, but this study did not report imaging findings.[10] With this in mind, we suspect that in this case the athlete experienced an acute inflammatory response in the Achilles paratenon before ATR, leading to significant thickening. Of note, the postinjury magnetic resonance imaging was notable for severe tendinosis of the remnant distal Achilles tendon, which was not noted on ultrasound just 2 wks prior, indicating that paratenon thickening may be a precursor to rapidly developing tendon damage. Thus, it is plausible that in this case, and in the case of ATR in young athletes, the paratenon acute stress response may predispose the athlete to tendon rupture. However, it is also possible that the noted paratenon thickening is a normal healing response, without specific augmentation of the subsequent risk of ATR.

Little is known regarding the expected timeline of isolated paratenon proliferation and recession in the process of healing and recovery from injury, in the absence of ATR. The concept of paratenonitis has previously been described,[11,12] but there are no studies that specifically evaluate its development and change over time. Previous studies investigating the role of the Achilles paratenon have almost exclusively focused on its contribution to associated Achilles tendon pain and pathology.[13] Similarly, it is unknown how paratenon healing may be affected by non-steroidal anti-inflammatories, if at all, such as the meloxicam that was prescribed to this athlete. The authors note seeing several cases of symptomatic posterior ankle pain with active paratenon thickening on ultrasound, and none have previously gone on to rupture their Achilles tendons. Thus, the cause of paratenon thickening and the role of paratenonitis in progression to ATR remain incompletely understood.

It should be noted that this case is limited by a lack of histopathological examination of the paratenon and Achilles tendon in question after the rupture. It is also limited by ultrasound examinations at only two time points before rupture, whereas more longitudinal serial imaging could further clarify the timeline of paratenon thickening in relation to injury. More reports are needed to better characterize the role of the Achilles paratenon before ATR.

In summary, this case study describes a male collegiate lacrosse athlete with normal asymptomatic sonographic imaging 7 mos prior, followed by paratenon thickening but normal Achilles tendon appearance on repeat ultrasound examination 2 wks before a complete midsubstance Achilles tendon rupture. This calls into question both the role of the paratenon in similar Achilles tendon ruptures in the young athlete population, as well as the clinical care guidelines of an athlete found to have an acutely thickened paratenon. For athletes in explosive sports, extra caution may be warranted when paratenon thickening is noted acutely on ultrasound.

REFERENCES

1. Knobloch K, Yoon U, Vogt PM: Acute and overuse injuries correlated to hours of training in master running athletes. *Foot Ankle Int* 2008;29:671–6
2. Bonanno J, Cheng J, Tilley D, et al: Factors associated with Achilles tendon rupture in women's collegiate gymnastics. *Sports Health* 2022;14:358–68
3. Lantto I, Heikkinen J, Flinkkilä T, et al: Epidemiology of Achilles tendon ruptures: increasing incidence over a 33-year period. *Scand J Med Sci Sports* 2015;25:e133–8
4. Tallon C, Maffulli N, Ewen SW: Ruptured Achilles tendons are significantly more degenerated than tendinopathic tendons. *Med Sci Sports Exerc* 2001;33:1983–90
5. Müller SA, Evans CH, Heisterbach PE, et al: The role of the paratenon in Achilles tendon healing: a study in rats. *Am J Sports Med* 2018;46:1214–9
6. Ahmed IM, Lagopoulos M, McConnell P, et al: Blood supply of the Achilles tendon. *J Orthop Res Off Publ Orthop Res Soc* 1998;16:591–6
7. Weinfeld SB: Achilles tendon disorders. *Med Clin North Am* 2014;98:331–8
8. Cushman DM, Catalano E, Hoffman J, et al: Achilles tendon rupture preceded by normal asymptomatic imaging in a collegiate gymnast: a case report. *Radiol Case Rep* 2024;19:3470–2
9. Hess GW: Achilles tendon rupture: a review of etiology, population, anatomy, risk factors, and injury prevention. *Foot Ankle Spec* 2010;3:29–32
10. Kobayashi JK, Kobayashi EF, Tomasevich KM, et al: Characterization of Achilles tendon ruptures in collegiate women's gymnastics. *Orthopedics* 2023;46:205–10
11. Kvist M, Józsa L, Järvinen MJ, et al: Chronic Achilles paratenonitis in athletes: a histological and histochemical study. *Pathology (Phila)* 1987;19:1–11
12. Medina Pabón MA, Naqvi U: Achilles tendinopathy. In: *StatPearls*. StatPearls Publishing; 2025. Available at: http://www.ncbi.nlm.nih.gov/books/NBK538149/. Accessed May 3, 2025
13. Stecco A, Busoni F, Stecco C, et al: Comparative ultrasonographic evaluation of the Achilles paratenon in symptomatic and asymptomatic subjects: an imaging study. *Surg Radiol Anat SRA* 2015;37:281–5

© 2025 Wolters Kluwer Health, Inc. All rights reserved.

Copyright © 2025 Wolters Kluwer Health, Inc. All rights reserved.